

# Nanofat in Facial Rejuvenation: Step-by-Step Procedure, Patient Evaluation and Recovery Process

The American Journal of  
Cosmetic Surgery  
0(0) 1–9  
© The Author(s) 2020  
Article reuse guidelines:  
sagepub.com/journals-permissions  
DOI: 10.1177/0748806820919935  
journals.sagepub.com/home/acs



Nabil Fakh-Gomez, MD, MSc<sup>1</sup> , Enosh Steward, MDS<sup>1</sup> and Maria del Carmen Orte Aldea, MD<sup>1</sup>

## Abstract

Several reports have been published wherein intradermal filling with nanofat has been used for skin rejuvenation, texture improvement and scar treatment. A study was conducted between August 2017 and August 2018 which included 20 female patients having wrinkles, hyperpigmentation, erythema, and enlarged pores. Lidocaine cream, local infiltration with lidocaine or sedation was used in accordance with the patient's convenience. Nanofat was injected intradermally in all the facial regions. All patients filled a questionnaire at sixth month post treatment which consisted of questions regarding pain, bumps area and resolution, grade of improvement of skin (wrinkles, smoothness, wrinkles, pores and redness), recovery of donor area, time to reincorporate to normal routine, nanofat-time efficacy and recommendation of the treatment. Patients undergoing it with sedation had less bruising and pain. Lateral thigh as the donor area had less pain in the recovery period. The residual bumps persisted for more time in non-mobile areas while average time to disappear was 3.6 weeks. Patients started to notice the change after nanofat injections at about 1.12 months later. The improvement was noticed for smoothness of skin (100% patients), wrinkles (40% patients), pore size reduction (15% patients), improvement in redness (10% patients). The effect of nanofat was felt by patients for an average time of 3.85 months. All the patients were satisfied and recommended it. No major complications were reported. Nanofat treatment is safe and it conveys beneficial effects on skin rejuvenation as per the post-operative skin texture changes and the satisfaction of patients.

## Keywords

nanofat, regenerative medicine, adipose stem cells, facial rejuvenation

## Introduction

Aging of the skin is a multifactorial process that involves intrinsic and extrinsic factors.

Coleman<sup>1</sup> revolutionized autologous fat grafting in his defined protocol. There has been a resurgence in fat grafting techniques, such as macrofat, microfat, sharp-needle intradermal fat grafting (SNIF), and sharp-needle intradermal emulsified fat grafting (SNIE).

In 2013, Tonnard et al<sup>2</sup> produced “nanofat,” or filtered lipids made by the mechanical emulsification of microfat, which contains tissue stromal vascular fraction (t-SVF) and adipose-derived stem cells (ASCs). Thus, ASCs have important regenerative and rejuvenative properties.<sup>3–5</sup> Several reports have been published regarding the use of nanofat as an intradermal filler for skin rejuvenation, texture improvement and scar treatment.<sup>6–9</sup>

Our study aims to provide step-by-step details regarding the harvesting, processing and injection of nanofat, as well as a discussion of our results, potential complications and the recovery process.

## Material and Methods

### Patients

This study was conducted at Fakh Hospital, Khaizaran, Lebanon, between August 2017 and August 2018 and

<sup>1</sup>Fakh Hospital, Khaizaran, Lebanon

### Corresponding Author:

Nabil Fakh-Gomez, Chief, Department of Facial Plastic & Cranio-Maxillo-Facial Surgery, Fakh Hospital, Khaizaran, Lebanon.  
Email: info@drnabifakh.com

included 20 patients with wrinkles, erythema, and enlarged skin pores. The patients had a mean BMI of  $27.99 \pm 1.27$  and ranged in age from 29 years to 46 years (mean: 36.8 years). All patients had skin types between I and IV. Exclusion criteria were patients with local ulcers, pregnancy, infectious diseases, autoimmune diseases, cancer, or coagulation defects, as well as those using skin cream treatments. Lidocaine 10.56% cream, local infiltration with lidocaine HCl 2% and epinephrine 1:1,000,000 or sedation was used in accordance with the patient's convenience. After treatment, all patients were given empirical amoxicillin clavulanate 1 g three times a day for seven days, oral cortisone for five days, and sunscreen for six months.

### **Donor Site Selection**

Potential donor sites were identified and included the lower abdomen and thighs.

### **Instrumentation and Materials**

The patented Tulip Medical™ system (Tulip Medical Products, San Diego, CA) was used to harvest and process the fat. The sets needed for the procedure are the Tulip Gold Standard Facial Set™ and Tulip Nanotransfer Reusable Starter Set™, with standard Luer Lock syringes of 1 cc, 10 cc, 20 cc, and 11 no. In addition, we utilize a Bard-Parker blade, betadine solution, modified Klein's tumescent solution, sterile gauzes, 10.56% lidocaine cream, and 32 G needles.

### **Preparation of Lipoaspiration Sites**

Patients should be marked in an upright or standing position in order to effectively mark the area of available or unwanted adipose tissue deposits.

### **Fat Harvesting**

After skin preparation and draping, the modified Klein's tumescence, with 500 mL of NaCl 0.9% solution, 1 mg/mL of adrenaline (1:10,000) and 25 mL of lidocaine (20 mg/mL) is infiltrated slowly, using a tumescent infiltrator (2.1 mm × 20 cm) through a 2 mm incision made with a number 11 blade in the donor area via a "wet" infiltration technique. We manually harvested 120 cc of mixed fat with tumescent solution from subcutaneous fat in a "spokes-of-a-wheel" pattern using a Tonnard harvester 2.4 mm × 20 cm cannula, with sharp holes of 1 mm diameter, in a 20-mL Luer Lock syringe.

### **Processing and Washing**

The harvest syringe is capped in a vertical position to decant for 3-5 minutes to allow for separation of the layers. Within the syringe, the yellow adipose grafts

quickly separate from the underlying infranatant fluid according to their density, resulting in the grafts floating in the middle, on top of which is the lipid layer. A yield of 1.5 mL of fat graft per 5 mL of aspirate can be expected, and we acquire approximately 40 cc of microfat. The donor area is massaged and the tumescent solution is drained out of the incision, which is sutured using 6/0 nylon and covered with a sterile gauze dressing and external compression to minimize post-harvest bruising. The top liquid layer is removed into sterile containers for disposal. The oil layer above the harvested graft should not be aspirated into the syringe for preparing the microfat, as it can cause oil cysts and prolong the healing process. A single wash with Ringer's lactate solution should be performed to reduce residual local anesthetic solution and red blood cells.

### **Emulsification Process**

After decantation, the cleaned microfat is loaded into 20 cc syringes and mechanically emulsified by shifting the contents back and forth 30 times between two 20 cc syringes connected to each other by a 2.4 mm Tulip transfer, and then back and forth 30 times with a 1.4 mm Tulip transfer, and finally back and forth 30 times with a 1.2 mm Tulip transfer until the fat is liquefied and acquires a whitish appearance, which is termed as SNIE (sharp needle intradermal emulsified fat grafting) because it is injected with a 25 G needle.<sup>2</sup>

### **Nanofat Process**

The emulsified fat is passed through the nanotransfer block one time, which contains a double filter of 400 μm and 600 μm single use cartridge net (Tulip Medical Products, San Diego, CA), and into a 20 cc syringe. This nanofat is transferred into 1 cc Luer Lock syringes for injection.

### **Nanofat Injection**

The skin is prepared using betadine and local anesthetic cream (10.56% lidocaine). A local anesthetic injection or sedation could be another option if required. Nanofat is injected intradermally, forming small papule-like bumps over the entire facial skin (approximately 0.05-0.1 cc per injection point) using a 32 G sharp needle. The endpoint of the injection is reached with the appearance of a yellowish discoloration over the injection site, leaving approximately 1-2 mm bumps. A video demonstrating the technique is also available.<sup>10</sup>

### **Postoperative Treatment Aspects and Follow-Up**

Postoperative photographs were taken at 10-minute intervals after the procedure and at 1 week, 2 weeks,

3 weeks, 4 weeks, and 6 months using a Canon EOS 700D DSLR under the same environmental settings. All patients provided written consent regarding their participation in the study. The questionnaire was briefly explained to the patient after the procedure and consisted of questions regarding pain, bump area and resolution, grade of improvement of the skin (smoothness, wrinkles, redness, pores, scars, and hyperpigmentation), recovery of the donor area, time to resume their normal routine, visual efficacy of nanofat on the skin and recommendation of the treatment. Patients completed the questionnaire (Figure 1) at the 6-month follow-up visit.

## Results

All 20 patients (100%) in our study were females. Various methods of anesthesia, such as sedation (25%), local infiltration (30%), local creams and combination of local infiltration (30%) and local creams alone (15%) were used. On the Facial Pain Scale (Scale 1), which is graded from zero to five, with grade zero being no pain and grade five being hurts the most, four patients (20%) reported grade 0 or no pain (patients who underwent sedation); three patients (15%) reported grade one pain (combination of local infiltration and anesthetic cream); five patients (25%) reported grade two pain (local infiltration or anesthetic cream); six patients (30%) reported grade three pain (anesthetic cream), and two patients (10%) reported grade four pain (anesthetic injection). All patients had multiple lumps/bumps all over the face immediately after the procedure, which remained visible under the skin for an average of 3.6 weeks (range, 10 days to 8 weeks). The lumps/bumps were located in the parotid region (50% of patients), cheek area (40% of patients), angle of the mandible (15% of patients), and jaw area (15% of patients), as well as on the chin (10% of patients) and forehead (5% of patients).

The average length of time to when patients noticed changes after nanofat injections was 1.12 months (range, 3 weeks to 2.5 months). For assessing the grade of improvement, a scale ranging from grade one to grade five (Scale 2) was proposed, with grade one being no improvement and grade five being tremendously significant improvements. There were 13 patients (65%) who experienced moderate improvements (score 3), while seven patients (35%) experienced few or mild improvements (score 2). The improvements noticed were smoothness of skin (100% of patients), wrinkle reduction (40% of patients), pore size reduction (15% of patients), and less redness (10% of patients). The average time taken by the patients to resume their normal routine was 1.7 weeks (range, 1-3 weeks). The donor area chosen during the study for nanofat grafting was the lateral thigh in 16 cases (80%) and abdomen in four cases (20%).

Patients with a harvest site in the abdomen had more pain after recovery than those with a harvest site in the thigh area. The pain felt in the abdominal region was grade 3, which was moderate in intensity, and bruising was grade four out of five. The pain experienced in the thigh region ranged from grade one or no pain (20%) to grade two or mild pain (80%). The average time for complete recovery from pain and bruising in the donor site area was 2.05 weeks (range, 1–3 weeks). Redness and bruising were more pronounced in patients with sensitive skin or rosacea. Patients who underwent sedation or topical cream anesthesia had less inflammation than patients who underwent nerve block. The effect of nanofat was felt by the patients for an average duration of 3.85 months (range, 2–5 months). All patients (100%) were highly satisfied with the treatment and recommended the same. No complications were reported in relation to the donor area or the nanofat injection site. A case is shown before treatment, after 10 minutes of treatment, and at 1 week, 2 weeks, 3 weeks, 4 weeks, and 6 months after treatment (Figures 2–15). Skin improvement is shown in another case at baseline, at 3 weeks and at 6 months (Figures 16–18).

## Discussion

Nanofat contains SVF and ASC. The differentiation of ASC produces a large amount of type I collagen, smaller amounts of type V and type VI collagen and proteins, regenerates fibroblasts, and secretes greater amounts of cell matrix, all of which helps to repair dermal breaks and reconstruct and rehabilitate the skin structure, thus improving wrinkles.<sup>7</sup>

Studies about nanofat show an improvement in elasticity, which can be attributed to an increased synthesis of collagen and elastin, along with remodeling, which are triggered by stem cells of the adipocytes that are destroyed during the emulsification process.<sup>2</sup>

In 2013, Tonnard et al<sup>2</sup> performed the first study on nanofat grafting in 67 cases for the rejuvenation of perioral skin, sun damaged skin of the breast cleavage, dark lower eyelids and glabellar skin, and concluded that stem cells in the nanofat do not contain viable adipocytes but have ASC and SVF, which boost rejuvenation and are responsible for the improvements. In 2017, Tenna et al<sup>11</sup> published a study that concluded that the use of nanofat with PRP (platelet rich plasma) alone or in combination with a fractional CO<sub>2</sub> laser improved atrophic scars on the face in 30 patients with skin types between II and IV. Lo Furno et al<sup>12</sup> conducted a study on eight patients, with a modification in making nanofat, which they called nanofat 2.0. They had three samples of patients: one cohort was treated with microfat, another with nanofat, and the last one with nanofat 2.0. Nanofat was produced by adhering to the protocol

**Questionnaire for patients**

Name: \_\_\_\_\_ Age: \_\_\_\_\_ Gender: \_\_\_\_\_

1. What problems you want to improve ?

Size of pores    Smooth of skin    Redness    Scars


Wrinkles    Hyperpigmentation

2. Type of Anesthesia ? \_\_\_\_\_

3. Was the procedure painful? :

(Scale 1: Face Rating Pain Scale)

"Faces" Pain Rating Scale



4. When did your bumps disappear?: \_\_\_\_\_

5. Which was the place where the bumps persist more time ? \_\_\_\_\_

6. When did you notice improvement on your skin? \_\_\_\_\_

7. Which grade of improvement have you noticed?: 1   2   3   4   5

(Scale 2: Scale from 1 to 5 (1 is no or never, 2 few or mild, 3 is moderately, 4 is a lot or often and 5 is very much or severe))

8. Which was the most important improvement on your skin?:

Size of pores    Smooth of skin    Redness    Scars

Wrinkles    Hyperpigmentation

9. When did you reincorporate to your routine? \_\_\_\_\_

10. Recovery donor area:

Abdomen:

Pain:	0	1	2	3	4	5	(Use Scale 1)
Bruising:	1	2	3	4	5		(Use Scale 2)

Time of complete recovery: \_\_\_\_\_

Thigh:

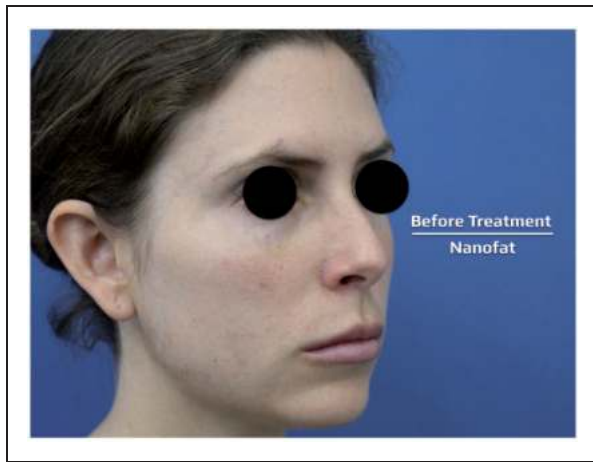Pain:	0	1	2	3	4	5	(Use Scale 1)
Bruising:	1	2	3	4	5		(Use Scale 2)

Time of complete recovery: \_\_\_\_\_

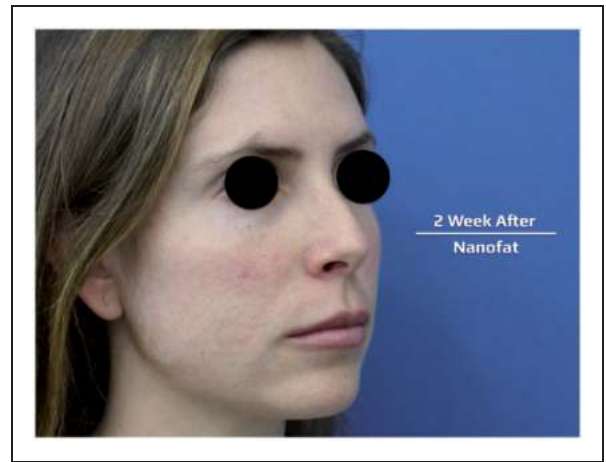11. How long have you noticed the effect of nanofat? \_\_\_\_\_

12. Do you recommend this treatment?    Yes    No

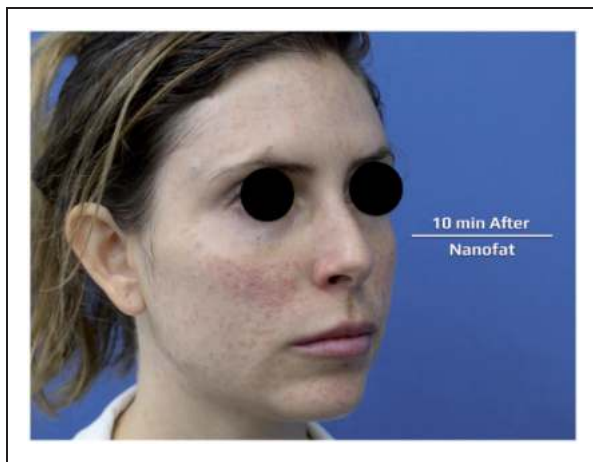
Figure 1. Questionnaire for patients.



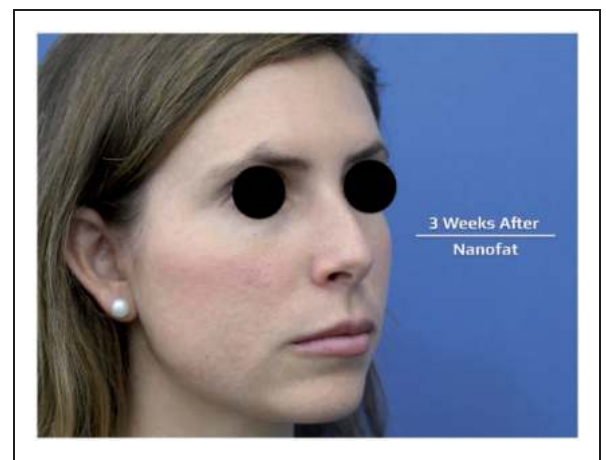**Figure 2.** Right third-quarter view of a patient of 33 years old with redness, pores and wrinkles before treatment of nanofat injection.



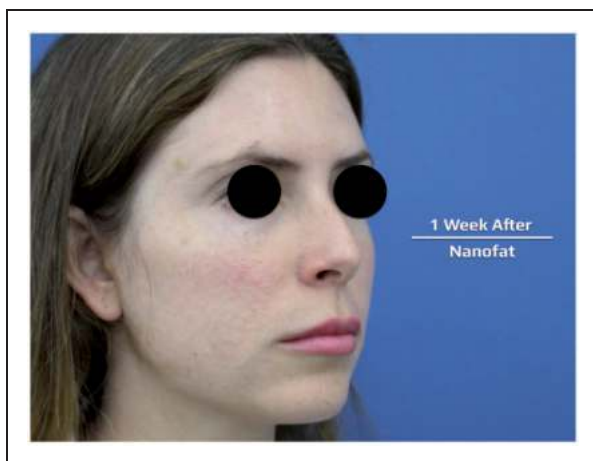
**Figure 5.** After 2 weeks.



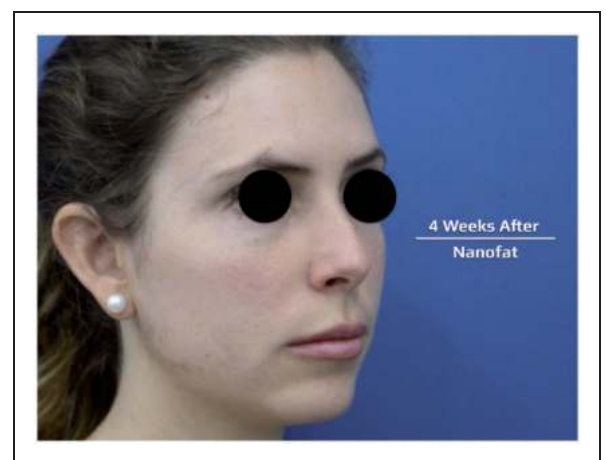**Figure 3.** After 10 minutes.



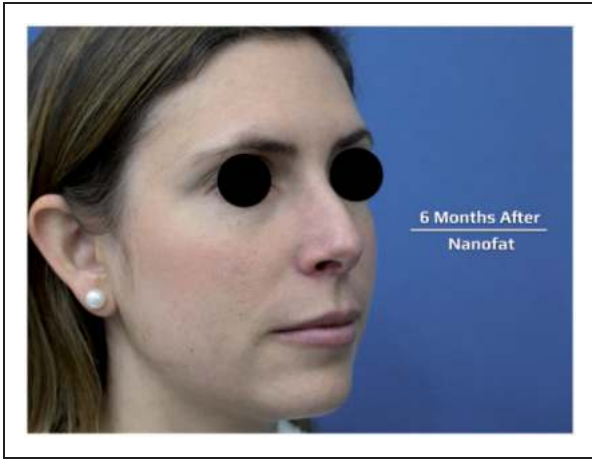**Figure 6.** After 3 weeks.



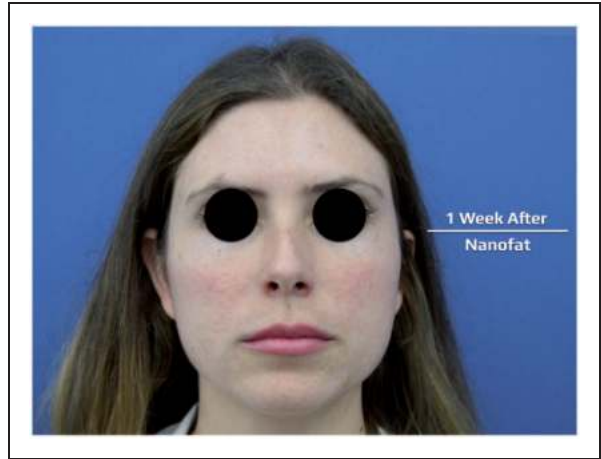**Figure 4.** After 1 week.



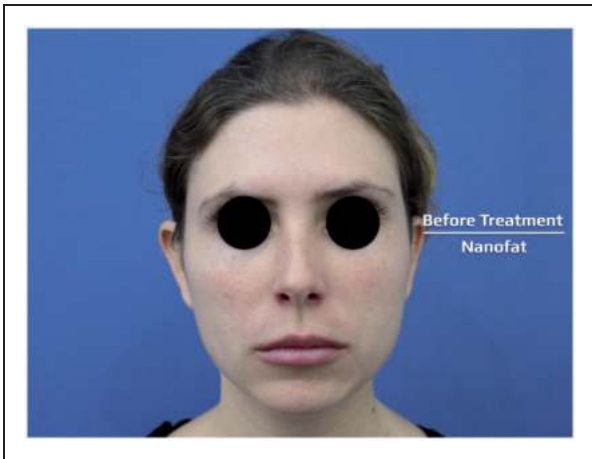**Figure 7.** After 4 weeks.



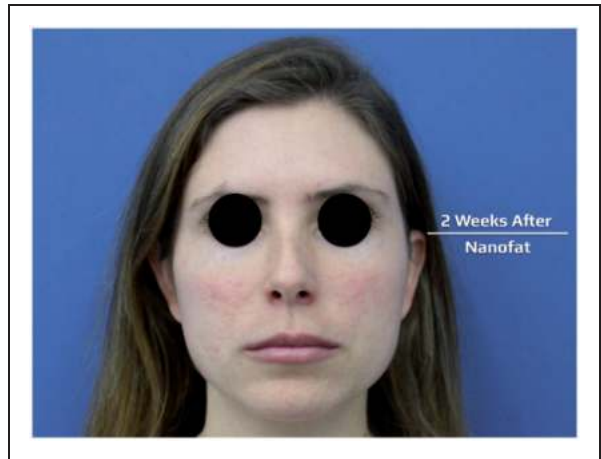**Figure 8.** After 6 months of nanofat injection. She has undergone filler injection 0.5 ml of hyaluronic acid in every cheek.



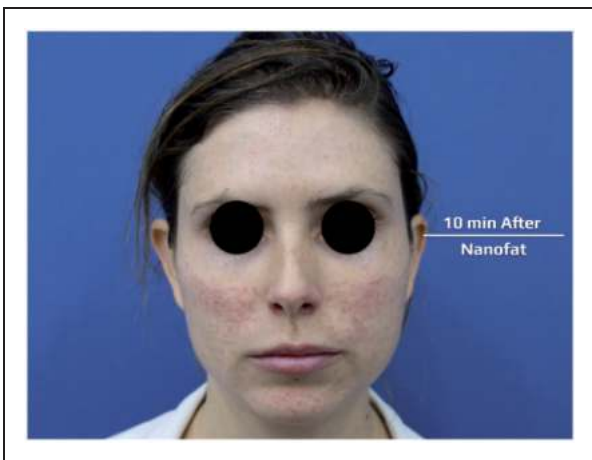**Figure 11.** After 1 week.



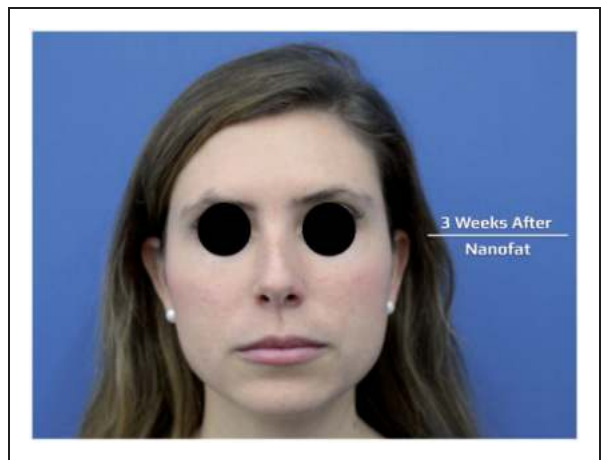**Figure 9.** Anteroposterior view of a patient of 33 years old with redness, pores and wrinkles before treatment of nanofat injection.



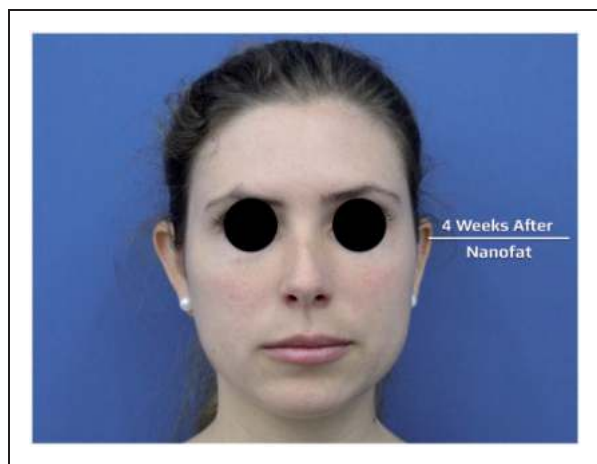**Figure 12.** After 2 weeks.



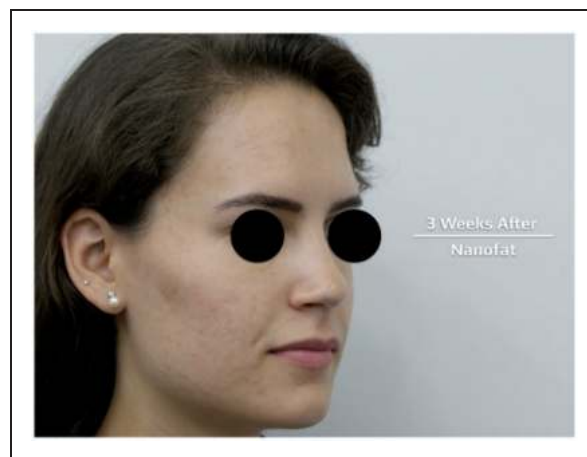**Figure 10.** After 10 minutes.



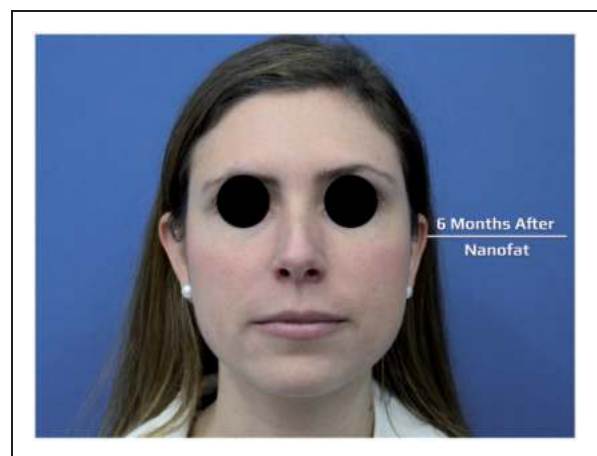**Figure 13.** After 3 weeks.



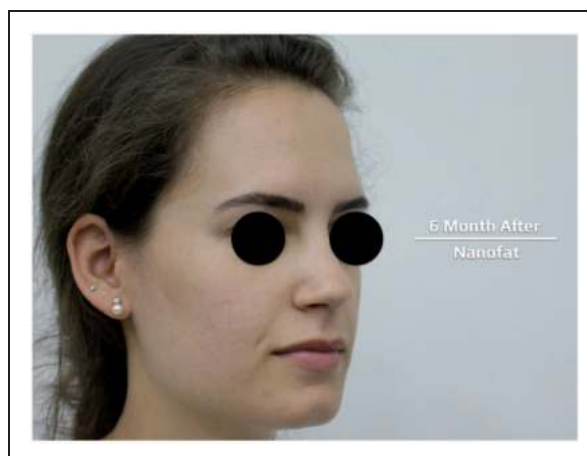**Figure 14.** After 4 weeks.



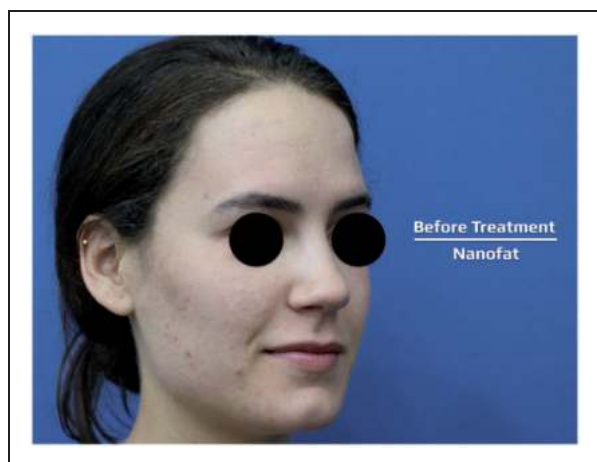**Figure 17.** After 3 weeks.



**Figure 15.** After 6 months of nanofat injection. She has undergone filler injection 0.5 ml of hyaluronic acid in every cheek.



**Figure 18.** After 6 months.



**Figure 16.** Right third-quarter view of a patient of 33 years old before the nanofat injection treatment.

of Tonnard et al.<sup>2</sup> The nanofat 2.0 was obtained through the same Tonnard's procedure but by avoiding the final phases of filtering and squeezing the fat emulsion through the gauze. The results showed that the nanofat 2.0 emulsion is considerably rich in stem cells, thus featuring a marked proliferation capability.

Wei et al<sup>13</sup> concluded in his study of 62 patients who mixing nanofat and PRF and injecting the mixture via cannula improved skin texture, elasticity, pore size, moisture and facial tissue depression, with an overall satisfaction rate over 90%. Xu et al<sup>7</sup> demonstrated increased dermis thickness and neo-vascularization in photoaged skin after 4 weeks of nanofat injection. Nanofat has been demonstrated to improve wrinkles, discolorations, and scars.<sup>9,13-15</sup> In 2018, Liang et al<sup>16</sup> conducted a study with 128 patients, comparing the combination of PRF and nanofat to hyaluronic acid filler. They concluded that injecting PRF and nanofat

significantly improved the facial texture compared to hyaluronic acid filler.

All these studies support the idea rejuvenation to offer to our patients. The technique is simple and well detailed in this article. The minimum amount of fat required for an intradermal nanofat injection is between 30–40 cc (average, 35 cc per person), with a treatment that can be performed under local anesthesia or sedation in the clinic. A major concern with sharp needle injections in the face is the rare occurrence of intravascular injection, with embolization of certain vascular territories. This can lead to skin necrosis at the injection site<sup>17–19</sup> and even more catastrophic problems, such as blindness or cerebral stroke. In nanofat treatment, we inject into the superficial dermis, which has a lower risk for embolization using 32 G needles. Very few problems—minimal redness, swelling, and bruising—were encountered with the nanofat procedure. Bruising was the most common adverse effect (100% of patients). No major complications were encountered. Transitory problems that may occur include palpable nodules or lumpiness in the dermis, which was the main concern for all our patients since they took time to resolve; the addition of heparinoid cream reduced the lumpiness at a faster pace. To reduce recovery time, we tried mixing PRP into nanofat at a 1:1 ratio, which seemed to reduce the recovery time by half. However, this mixture requires further studies to compare it to nanofat injections. The bumps persisted for a longer time in less mobile areas, such as the parotid region or lateral cheek, compared to more active areas, such as the lips and glabella. No fat necrosis or fat cysts were observed, probably due to a lack of viable fat cells in the nanofat.

The limitation of the present study is that the skin improvement results are not quantifiable. However, we are currently preparing larger studies to evaluate skin texture, pores and pigmentation. To our knowledge, step-by-step details of the nanofat technique for intradermal fat injection and its recovery process have not previously been described in the literature. This article is proposed as a valuable supplement to doctors who would like to initiate this treatment in their clinic.

## Conclusion

In our study, we demonstrated a step-by-step representation of nanofat treatment and the recovery process. We conclude that nanofat treatment conveys beneficial effects on skin rejuvenation, per the postoperative skin texture changes and patient satisfaction. No surface irregularities or lumpiness were seen in any of the patients after six months. This technique is safe and has a feasible application, with low tissue morbidity, making it a newer tool in facial rejuvenation and restoration, particularly for improving skin texture. The only

drawback of this study is the small sample size; thus, further studies with larger sample sizes should be carried out in this field to provide better literature.


## Declaration of Conflicting Interests

The author(s) declared no potential conflicts of interest with respect to the research, authorship, and/or publication of this article.

## Funding

The author(s) received no financial support for the research, authorship, and/or publication of this article.

## ORCID iD

Nabil Fakh-Gomez  <https://orcid.org/0000-0003-4464-8258>

## References

1. Coleman SR. Structural fat grafting: more than a permanent filler. *Plast Reconstr Surg*. 2006;118:108S–120S.
2. Tonnard P, Verpaele A, Peeters G, Hamdi M, Cornelissen M, Declercq H. Nanofat grafting: basic research and clinical applications. *Plast Reconstr Surg*. 2013;132:1017–1026.
3. Oh JS, Park IS, Kim KN, Yoon DH, Kim SH, Ha Y. Transplantation of an adipose stem cell cluster in a spinal cord injury. *NeuroReport*. 2012;23:277–282.
4. Zhou B, Yuan J, Zhou Y, et al. Administering human adipose-derived mesenchymal stem cells to prevent and treat experimental arthritis. *Clin Immunol*. 2011;141:328–337.
5. Kapur SK, Katz AJ. Review of the adipose derived stem cell secretome. *Biochimie*. 2013;95:2222–2228.
6. Uyulmaz S, Sanchez Macedo N, Rezaeian F, Giovanoli P, Lindenblatt N. Nanofat grafting for scar treatment and skin quality improvement. *Aesthet Surg J*. 2019;38(4):421–428.
7. Xu P, Yu Q, Huang H, Zhang WJ, Li W. Nanofat increases dermis thickness and neovascularization on photoaged nude mouse skin. *Aesthetic Plast Surg*. 2018;42(2):343–351.
8. Jan SN, Bashir MM, Khan FA, et al. Unfiltered nanofat injections rejuvenate postburn scars of face. *Ann Plast Surg*. 2019;82(1):28–33.
9. Gu Z, Li Y, Li H. Use of condensed nanofat combined with fat grafts to treat atrophic scars. *JAMA Facial Plast Surg*. 2018;20(2):128–135.
10. [www.youtube.com/watch?v=2-0exTbHlto&t=470s](https://www.youtube.com/watch?v=2-0exTbHlto&t=470s).
11. Tenna S, Cogliandro A, Barone M. Comparative study using autologous fat grafts plus platelet rich plasma with or without fractional CO2 laser resurfacing in treatment of acne scars: analysis of outcomes and satisfaction with FACE-Q. *Aesthetic Plast Surg*. 2017;41(3):661–666.
12. Lo Furno D, Tamburino S, Mannino G, et al. Nanofat 2.0: experimental evidence for a fat grafting rich in mesenchymal stem cells. *Physiol Res*. 2017;66:663–671.
13. Wei H, Gu SX, Liang YD, et al. Nanofat-derived stem cells with platelet-rich fibrin improve facial contour



- remodelling and skin rejuvenation after autologous structural fat transplantation. *Oncotarget*. 2017;8(40):68542–68556.
14. Jeong JH, Fan Y, You GY, Choi TH, Kim S. Improvement of photoaged skin wrinkles with cultured human fibroblasts and adipose-derived stem cells: a comparative study. *J Plast Reconstr Aesthet Surg*. 2015;68(3):372–381.
  15. Klinger M, Lisa A, Klinger F, et al. Regenerative approach to scars, ulcers and related problems with fat grafting. *Clin Plast Surg*. 2015;42(3):345–352.
  16. Liang ZJ, Lu X, Li DQ, et al. Precise intradermal injection of nanofat-derived stromal cells combined with platelet-rich fibrin improves the efficacy of facial skin rejuvenation. *Cell Physiol Biochem*. 2018;47:316–329.
  17. Glaich AS, Cohen JL, Goldberg LH. Injection necrosis of the glabella: protocol for prevention and treatment after use of dermal fillers. *Dermatol Surg*. 2006;32(2):276–281.
  18. Inoue K, Sato K, Matsumoto D, Gonda K, Yoshimura K. Arterial embolization and skin necrosis of the nasal ala following injection of dermal fillers. *Plast Reconstr Surg*. 2008;121(3):127e–128e.
  19. Georgescu D, Jones Y, McCann JD, Anderson RL. Skin necrosis after calcium hydroxylapatite injection into the glabellar and nasolabial folds. *Ophthalm Plast Reconstr Surg*. 2009;25:498–499.

### Author Biographies

**Nabil Fakih-Gomez**, MD, MSc, is the Chief of department of Facial Plastic & Cranio-Maxillo-Facial Surgery and former Vice-President of the Spanish Society of Facial Plastic Surgery Fakih Hospital, Khaizaran, Lebanon.

**Enosh Steward**, MDS, is a consultant at Maxillofacial Surgery Chandan Hospital, Vadodara, India.

**Maria del Carmen Orte Aldea**, MD, is a consultant at Otorhinolaryngology and Head and Neck Surgery Barbastro Hospital, Huesca, Spain.