

# Fat Grafting and Breast Augmentation: A Systematic Review of Primary Composite Augmentation

Ara A. Salibian, MD  
Jordan D. Frey, MD  
Jonathan M. Bekisz, MD  
Mihye Choi, MD  
Nolan S. Karp, MD

**Background:** Fat grafting during primary breast augmentation has the ability to address the limitations of soft tissue coverage of breast implants. The purpose of this study was to evaluate the current evidence on patient selection, surgical techniques, and assessment of outcomes with composite breast augmentation.

**Methods:** A systematic review of the literature was performed for studies reporting on primary composite breast augmentation. Studies were analyzed for level of evidence, surgical techniques for implant placement and fat grafting, postoperative complications, and assessment of additional outcomes.

**Results:** Five studies (4 case series and 1 retrospective cohort study) were identified for review with a pooled total of 382 patients. Implants were most commonly placed in the subfascial plane (156 patients, 54.1%) followed by dual-plane placement (51 patients, 17.6%). Round (220 patients, 57.6%) and textured (314 patients, 82.2%) implants were utilized in the majority of cases. The average amount of fat grafted among all 5 studies was 109.2 ml per breast (range 55–134 ml). The most common fat grafting location was in the subcutaneous plane and over the medial breast/cleavage (80% of studies). Overall complication rates were low. The pooled reoperation rate was 3.7% with repeat fat grafting as the most common reason for reoperation (9 cases, 2.4%).

**Conclusions:** Primary composite breast augmentation is a safe procedure with a trend toward subfascial implant placement and low fat grafting volumes focused on the medial breast borders. Long-term studies with analysis of additional outcome measures including patient-reported outcomes will further bolster the current evidence. (*Plast Reconstr Surg Glob Open* 2019;7:e2340; doi: 10.1097/GOX.0000000000002340; Published online 24 July 2019.)

## INTRODUCTION

Breast augmentation is the most common cosmetic plastic surgery procedure performed in the United States.<sup>1</sup> Patient satisfaction after this procedure is high<sup>2,3</sup> and long-term complication rates have been acceptably low.<sup>4,5</sup> However, certain challenges in breast augmentation remain, despite advances in implant technology and operative techniques.

Achieving adequate soft tissue coverage of the implant has been a persistent challenge in breast augmentation, particularly in thin patients with severe hypomastia. A

paucity of breast tissue and subcutaneous fat can portend a poor cosmetic result despite excellent enhancement of volume and projection, due to the inability to hide the presence of the prosthesis under the patient's native tissue. This mismatch between size and soft tissue coverage<sup>6</sup> results in implant palpability, edge visibility, and often rippling, all of which are disconcerting to both the patient and surgeon.

Several different techniques have been utilized in an attempt to better conceal breast implants in patients with a poor soft tissue envelope. Implant placement in the subpectoral space or utilizing a dual-plane pocket<sup>7</sup> increases overlying soft tissue coverage under varying amounts of the pectoralis major. Highly cohesive, form-stable anatomic implants have demonstrated decreased rates of wrinkling and rippling.<sup>8</sup> Adjunctive materials such as acellular dermal matrix have also been utilized to improve soft tissue coverage and address soft tissue envelope complications.<sup>9</sup>

Primary fat grafting at the time of breast augmentation has emerged as another tool to better maintain natural

From the Hansjörg Wyss Department of Plastic Surgery, New York University Langone Health; New York, N.Y.

Received for publication April 9, 2019; accepted May 7, 2019.

Copyright © 2019 The Authors. Published by Wolters Kluwer Health, Inc. on behalf of The American Society of Plastic Surgeons. This is an open-access article distributed under the terms of the Creative Commons Attribution-Non Commercial-No Derivatives License 4.0 (CCBY-NC-ND), where it is permissible to download and share the work provided it is properly cited. The work cannot be changed in any way or used commercially without permission from the journal.

DOI: 10.1097/GOX.0000000000002340

**Disclosure:** The authors have no financial interest to declare in relation to the content of this article.

breast shape and conceal the underlying prosthesis while augmenting breast size. Composite breast augmentation refers to the principle of combining prosthetic implants and autologous fat to manage the core volume and overlying soft tissue of the breast, respectively.<sup>6</sup> The use of both implants and autologous fat allows the surgeon to have independent control over breast volume using implants, and breast shape using autologous fat.<sup>10</sup> In this regard, composite augmentation circumvents some of the limitations of implant-only augmentation in patients with a deficient soft tissue envelope, manages breast asymmetries more precisely, and obtains the desired breast shape in a more refined manner.

Although fat grafting to the breast has seen widespread use in many areas of breast surgery, the use of autologous fat at the time of primary breast augmentation is a relatively new concept<sup>6</sup> that continues to evolve as new reports emerge. The purpose of this study was to better understand the current evidence on composite breast augmentation by pooling data from individual reports. A systematic review was performed to evaluate the available evidence on appropriate patient selection, the utility of particular techniques, and the assessment of outcomes to further analyze the efficacy of this procedure and determine the need for future areas of focused research.

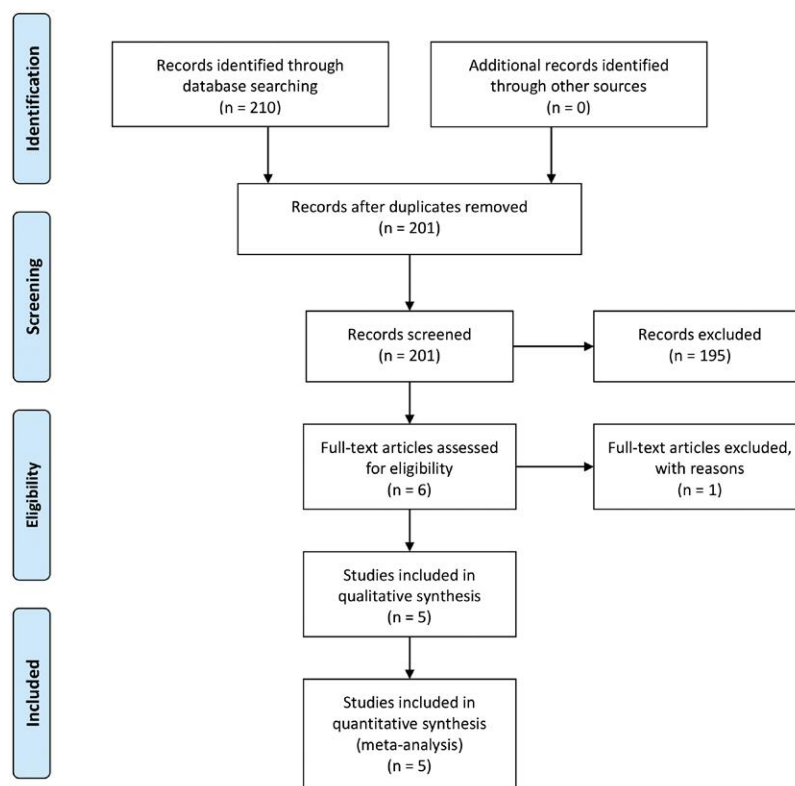
## METHODS

A systematic review of the current literature on primary composite breast augmentation was performed accord-

ing to Preferred Reporting Items for Systematic Reviews and Meta-analyses<sup>11</sup> guidelines. A literature search was conducted in the Medline database using the keywords “breast augmentation,” “fat grafting,” “fat,” “composite,” and “augmentation mammoplasty.”

After duplicates were removed, abstracts for original-research, English-language studies were screened by 2 reviewers independently (A.A.S. and J.M.B). Manuscripts that reported a clinical series of patients with primary composite breast augmentation were reviewed. No restrictions were placed on reported levels-of-evidence. Review articles and abstracts without available full-text manuscripts were excluded. In addition, papers that included experiences of authors reported in prior included papers were excluded from analysis. Only manuscripts that included data on primary composite breast augmentation were chosen. Studies on both primary and secondary/revision augmentation were included if data on primary composite augmentation was able to be independently extracted upon further analysis of the paper.

References from selected articles were additionally queried for other relevant studies. Any disagreement on study inclusion was resolved by discussion between the two reviewers. Figure 1 summarizes the literature selection process according to Preferred Reporting Items for Systematic Reviews and Meta-analyses guidelines. A total of 201 abstracts were screened which resulted in the evaluation of 6 full-text manuscripts, of which one was excluded for prior reported data for a total of 5 manuscripts included for qualitative and quantitative analysis.



**Fig. 1.** Flow diagram for literature search according to Preferred Reporting Items for Systematic Reviews and Meta-Analyses guidelines.

**Table 1. Summary of Included Studies**

Authors	Year	Study Design (LOE)	Patients/Breasts	Follow-up (mo)
Auclair et al <sup>6</sup>	2013	CS (IV)	140/280	5 (mean)
Bravo <sup>12</sup>	2015	RCS (III)	21/42	—
Kerfant et al <sup>13</sup>	2017	CS (IV)	156/312	22.3 (mean)
Özalp and Aydinol <sup>14</sup>	2017	CS (IV)	34/68	22 (mean)
Maione et al <sup>15</sup>	2018	CS (IV)	31/62	3–12 (range)

CS, case series; LOE, level of evidence; RCS, retrospective cohort study.

Included studies were analyzed for study quality and level-of-evidence of the reported data. Data on implant placement techniques were tabulated including plane of implant placement, type of implants utilized, and access incisions. Reported fat grafting techniques were analyzed for methods of autologous fat harvest, fat preparation, and fat deposition. Assessed outcomes included short-term complications, capsular contracture, adverse outcomes secondary to fat grafting and reoperation rates and indications. Studies were also evaluated for assessment of additional outcomes including cosmetic results, volumetric analysis, and patient-reported outcomes.

Data were extracted only for articles that adequately reported results or variables in question. When appropriate, this data were combined to obtain pooled rates for particular outcomes. Descriptive statistics and measure of central tendency were used to describe absolute and mean results, respectively. Ninety-five percent confidence intervals (CIs) were determined for these proportions accordingly.

## RESULTS

A total of 5 studies were included for analysis (Table 1).<sup>6,12–15</sup> The majority of studies were level IV evidence case series (80%) with one study presenting a retrospective cohort study comparing implant-only to composite breast augmentation with parasternal fat grafting.<sup>12</sup> One study also reported cases of revision/secondary composite breast augmentation.<sup>6</sup> Pooling data from all studies resulted in a total of 382 patients (764 breasts) that underwent primary composite breast augmentation. Average follow-up was reported in 3 studies<sup>6,13,14</sup> with a pooled mean of 16.4 months and a range of 3–22.3 months when cited.

Strict inclusion and exclusion criteria for composite breast augmentation were generally not reported by studies although several broad criteria for the consideration of composite augmentation were described. Typically, patients were thin, with a low BMI, significant hypomastia, and minimal subcutaneous tissue in the breast. The overlying soft tissue envelope was evaluated with a standard pinch test in certain studies with more objective criteria for concomitant fat grafting including a pinch test of less than 2–3 cm.<sup>14</sup>

Pooled analysis of surgical techniques for prosthesis implantation (Table 2) revealed the subfascial plane as the most common location for implant augmentation (157 patients, 54.1%), followed by dual-plane augmentation (51 patients, 17.6%). One study did not quantitatively

**Table 2. Pooled Implant Characteristics and Operative Techniques**

Characteristics	Pooled n	Pooled %
Implant plane (n = 290)*		
Subfascial	157	54.1
Dual plane	51	17.6
Submuscular	48	16.6
Subglandular	34	11.7
Implant shape (n = 382)		
Round	220	57.6
Anatomic	162	42.4
Implant texture (n = 382)		
Smooth	68	17.8
Textured	314	82.2
Incision†		
Inframammary	3	60
Periareolar	3	60
Transaxillary	2	40

\*Subfascial and subglandular augmentation were not differentiated for 92 cases.

†Number and percentage of included studies. Three studies utilized more than one type of access incision.

differentiate between subfascial and subglandular implant planes.<sup>6</sup>

Round implants (220 patients, 57.6%) were more commonly utilized than anatomic (162 patients, 42.4%), and textured implants (314 patients, 82.2%) more than smooth (68 patients, 17.8%). Average implant size was reported in 3 studies,<sup>6,13,14</sup> with a pooled mean implant size of 277.3 cm<sup>3</sup>, range 140–850 cm<sup>3</sup> (n = 333 patients). Incisional access was not reported per case in several studies but was often instead reported descriptively as part of the operative technique. Analyzed in this fashion, inframammary and periareolar incisions were most common, each reported by 3 studies, followed by transaxillary incisions utilized in 2 studies. Additionally, 3 studies utilized more than one type of access incision.<sup>6,12,13</sup>

Fat grafting techniques were also analyzed (Table 3). Fat graft harvest sites were reported in 4 studies<sup>6,12,13,15</sup> and most commonly include the abdomen (75% of studies) and the hip/flank (75%). Three-millimeter cannulas were utilized in 100% of studies. Hand-held liposuction was more commonly performed than suction-assisted liposuction (60% versus 40%), and the majority of studies prepared fat by centrifugation (80%). All authors grafted fat in the subcutaneous plane, whereas one study additionally grafted in the dermis and breast parenchyma.<sup>14</sup> The average amount of fat grafted among all five studies was 109.2 ml per breast (range 55–134 ml). The most common fat grafting locations were the medial breast or cleavage (80% of studies) and the anterior soft tissue envelope overlying the implant (60%).

Complication rates were reported in all 5 studies (Table 4) with the exception of grade II capsular contracture (reported in 4 studies)<sup>12–15</sup> and implant visibility/palpability (3 studies).<sup>13–15</sup> Complications secondary to fat grafting were low with 2 cases of fat necrosis and oil cysts each (0.5%). Grade II capsular contracture was reported in 10 patients (4.1%) and grade III/IV in 4 patients (1%). The overall reoperation rate was 3.7% with repeat fat grafting as the most common reason for reoperation (9 cases, 2.4%).

**Table 3. Fat Grafting Techniques**

Characteristics*	Pooled n (%)*	Auclair et al <sup>6</sup>	Bravo <sup>12</sup>	Kerfant et al <sup>13</sup>	Özalp and Aydinol <sup>14</sup>	Malone et al <sup>15</sup>
Harvest site†						
Abdomen	3 (75%)		Abdomen	Abdomen	—	Abdomen
Hip/flank	3 (75%)	Hip/flank	Hip/flank		—	Hip/flank
Thigh	2 (25%)		Thigh	Thigh	—	
Buttock	1 (25%)			Buttock	—	
Harvest cannula size (mm)						
2	1 (20%)					2
3	5 (100%)	3	3	3	3	3
4	0					
Harvest technique						
Hand held	3 (60%)		Hand held		Hand held	Hand held
Suction assisted	2 (40%)	Suction assisted		Suction assisted		
Fat preparation						
Centrifuge	4 (80%)	Centrifuge	Centrifuge	Centrifuge		Centrifuge
Filtration	1 (20%)				Filtration	
Fat grafting layer						
Subcutaneous	5 (100%)	Subcutaneous	Subcutaneous	Subcutaneous	Subcutaneous	Subcutaneous
Dermal	1 (20%)				Dermal	
Breast Parenchyma	1 (20%)				Breast parenchyma	
Fat grafting location						
Anterior breast	3 (60%)	Anterior		Anterior		Anterior
Medial (Cleavage)	4 (80%)	Medial	Medial	Medial		Medial
Lateral	1 (20%)					Lateral
Superior	1 (20%)					Superior
Lower pole	2 (40%)				Lower pole	Lower pole

\*Reported based on number of studies.  
†n = 4 (harvest site not reported by one study).

Other outcomes measures varied among included articles. One study analyzed volumetric changes<sup>6</sup> in a subset of 20 patients at 1 year postoperatively which demonstrated a volume retention of 59%. Two studies analyzed aesthetic outcomes by independent, study-specific measures, including improvement in the medial implant transition zone<sup>12</sup> and overall surgeon analysis of aesthetic results.<sup>15</sup> Patient-reported outcomes were quantified in 2 studies that demonstrated high patient satisfaction with results based on study-specific surveys.<sup>14,15</sup>

### DISCUSSION

Composite breast augmentation has emerged as a means of addressing certain inherent limitations of prosthetic implants in achieving ideal breast shape and contour while augmenting size. The addition of strategic fat grafting at the time primary breast augmentation has been reported to have numerous benefits.<sup>6,13,16,17</sup> These benefits stem from the ability of fat grafting to focally aug-

ment overlying soft tissue coverage and shape the breast beyond the limitations of an implant. Fat grafting allows for masking of implant edges in thin patients, improvement in cleavage, and enhanced upper pole fullness. In addition, improved soft tissue coverage secondary to lipofilling may also permit surgeons to select more superficial planes, rather than submuscular planes, for implant placement in patients with more limited soft tissue coverage.<sup>16</sup>

A systematic review of original articles on primary composite breast augmentation demonstrated a predominance of retrospective single-institution case series in the current literature. A single retrospective cohort study by Bravo<sup>12</sup> importantly demonstrated the improvement of cleavage and medial breast aesthetics with composite breast augmentation compared to implant-only augmentation. Higher level-of-evidence data are always needed, but can be difficult with a particular procedure. In the case of composite breast augmentation, prospective comparison of techniques is challenging given the ethics of performing implant-only augmentations in patients that would benefit from primary fat grafting. However, additional studies retrospectively comparing composite breast augmentation to patients with similar BMI, ptosis and breast size that underwent implant-only augmentation may further reinforce benefits of fat grafting with regards to minimizing sequelae of a deficient soft tissue envelope.

Most studies did not describe concrete selection criteria for determining candidates for composite breast augmentation. Although strict criteria were not cited, a general selection process for appropriate candidates can be fairly easily envisioned in analyzing selected patient populations across studies. These patients include thin women with very low BMI and minimal subcutaneous tissue in the breast on physical examination. In a separate ar-

**Table 4. Pooled Complication Rates**

Complications	n (%)*	95% CI
Hematoma	2 (0.5)	0.02–2
Infection	2 (0.5)	0.02–2
Capsular contracture		
II	10 (4.1)	2.2–7.5
III/IV	4 (1)	0.3–2.8
Implant visibility/palpability	4 (1.8)	0.5–4.7
Fat necrosis	2 (0.5)	0.02–2
Oil cysts	2 (0.5)	0.02–2
Repeat fat grafting	9 (2.4)	1.2–4.5
Implant exchange	2 (0.5)	0.02–2
Overall reoperation	14 (3.7)	2.1–6.1

\*n = 382, except grade II capsular contracture (n = 242) and implant visibility/palpability (n = 221).  
CI, confidence interval.



ticle, Sampaio Goes et al<sup>16</sup> more directly enumerate their selection criteria for primary composite augmentation which include severe hypomastia, BMI < 20, minimal upper pole coverage and a pinch test less than 2 cm. However, based on described benefits of concomitant lipofilling with implant augmentation, one may surmise that most typical patients presenting for augmentation mammoplasty may benefit from some degree of fat grafting, although the limitations of donor sites should also be considered in very thin patients. However, there remains room in future research to better define what patients are the optimal candidates, particularly with regards to the location and amount of lipofilling in individualized cases.

Analysis of surgical techniques demonstrated that implant placement was primarily in the subfascial plane. Subfascial breast augmentation is a well described technique.<sup>18,19</sup> The pectoralis fascia serves as a distinct layer that can contribute to further concealing implant edges and limiting displacement of the implant while avoiding the issues of animation deformity often associated with subpectoral placement. The additional soft tissue coverage provided by primary fat grafting often obviates the need for pectoralis coverage allowing expanded utilization of the subfascial plane in patients that may otherwise not be candidates. The pectoralis fascia additionally serves as a barrier between the implant pocket and the fat-grafting compartment. However, the utility of composite augmentation has also been demonstrated in both the dual and subglandular planes.<sup>6</sup> Although the final decision on implant plane is often secondary to surgeon preference, the addition of fat grafting at the time of augmentation increases the flexibility of these decisions.

Textured implants were also significantly more commonly utilized than smooth implants (82.2 versus 17.8%). Reasons for this predominance of textured prostheses may include limiting implant migration, malrotation in anatomic implants and capsular contracture in the subglandular plane. However, given the increasing evidence of the association of breast implant-associated anaplastic large cell lymphoma with textured implants,<sup>20</sup> consideration should be given to increased utilization of smooth prostheses. Particularly, in the subfascial and dual-plane pockets, adequate pocket control and prevention of implant migration can usually be achieved with meticulous dissection based on preoperative markings to ensure avoidance of overdissection.

Trends in fat grafting suggested a tendency toward atraumatic harvest techniques.<sup>21</sup> Centrifugation was also the primary method of fat processing, although the advantages of this technique over other processing methods are less clear.<sup>22,23</sup> Importantly, fat grafting was most commonly performed to the medial breast as this area is typically most deficient in thinner patients. Achieving natural cleavage can be very difficult with implants, which can paradoxically appear to widen the distance between breasts as described by Bravo et al.<sup>12</sup> The results reported by these authors and the trends across these clinical series highlight the utility of fat grafting in this particular problem area.

The average volume of grafted fat across studies was 109.2 ml per breast. Although this volume inherently has a range, it is not a particularly large volume of grafted material, highlighting the role of fat in composite augmentation as a shaping and blending tool rather than a method of achieving volume and projection, as in primary autologous fat augmentation.<sup>24</sup> The capacity for fat grafting, however, is dependent on the plane of implant placement with a greater potential space for fat grafting when implants are placed in a deeper plane.<sup>6</sup> In this regard, it is important avoid overfilling to limit graft ischemia and subsequent fat necrosis.

Overall, complication rates were low across studies, demonstrating the safety of primary composite breast augmentation upon analysis of pooled results. Importantly, rates of oil cysts and fat necrosis were low and mammographic findings reported by Auclair et al<sup>6</sup> did not demonstrate an increased incidence of concerning lesions, reinforcing the known safety of fat grafting.<sup>25,26</sup> Reoperation rates were also low compared with large series,<sup>4,5,8</sup> although this must be considered in the context of a significantly shorter follow-up length. Given the known resorption of portions of grafted fat, repeated fat grafting as the primary reason for reoperation can be expected.

Other important outcomes measures, including volumetric analysis, objective analysis of cosmetic outcomes, imaging findings, and patient-reported outcomes varied among different studies. Volumetric analysis, a critical evaluation of long-term fat grafting success, was only measured in one study. Auclair et al<sup>6</sup> reported a 57% volume retention in 20 patients at 1 year postoperatively, consistent with reported ranges of volume retention of fat grafts from prior studies.<sup>27</sup>

Özalp and Aydinol<sup>14</sup> and Maione et al<sup>15</sup> reported high rates of patient satisfaction with composite breast augmentation. Both studies, however, utilized study-specific, nonvalidated surveys to assess these outcomes. Although this data provide important preliminary information on patient satisfaction with this procedure, the use of validated surveys for patient-reported outcomes<sup>28</sup> will be valuable to appropriately evaluate patient satisfaction and quality of life.

Limitations of this study include a small sample of available studies in the literature given the relatively recent widespread adoption of composite breast augmentation techniques. Despite this, a large number of overall patients were included in pooled analysis of data. Heterogeneity among reporting of certain variables, such as fat grafting data, also precluded analysis of these factors in a case-based fashion and instead required analysis of certain variables by study. In addition, a meta-analysis of effect sizes was unable to be performed as only one comparative study reporting outcomes was found

## CONCLUSIONS

Composite breast augmentation provides the ability to address limitations of soft tissue coverage that can otherwise compromise aesthetic outcomes after implant-based breast augmentation. A systematic review of the

current literature demonstrated the safety of concomitant fat grafting at the time of primary breast augmentation. Analysis of pooled data revealed a trend towards subfascial placement of textured implants with fat grafting primarily of the medial breast borders. Future studies that address additional important long-term outcomes such as patient-reported measures, ideally in a comparative manner, will help reinforce the benefits of this technique while further refining its applicability.

**Nolan S. Karp, MD**

Hansjörg Wyss Department of Plastic Surgery  
New York University Langone Health  
305 East 47th Street, Suite 1A  
New York, NY 10017  
E-mail: Nolan.karp@nyumc.org

### REFERENCES

1. American Society of Plastic Surgeons. 2018 National Plastic Surgery Statistics. 2019. Available at <https://www.plasticsurgery.org/documents/News/Statistics/2018/plastic-surgery-statistics-report-2018.pdf>. Accessed March 16, 2019.
2. Diaz JF. Review of 494 consecutive breast augmentation patients: system to improve patient outcomes and satisfaction. *Plast Reconstr Surg Glob Open*. 2017;5:e1526.
3. Ng S, Pusic A, Parker E, et al. Patient-reported outcome measures for breast implant surgery: a pilot study. *Aesthet Surg J*. 2019;pii: sjz023.
4. Stevens WG, Calobrace MB, Alizadeh K, et al. Ten-year core study data for sientra's food and drug administration-approved round and shaped breast implants with cohesive silicone gel. *Plast Reconstr Surg*. 2018;141:7S–19S.
5. Spear SL, Murphy DK; Allergan Silicone Breast Implant U.S. Core Clinical Study Group. Natrelle round silicone breast implants: core study results at 10 years. *Plast Reconstr Surg*. 2014;133:1354–1361.
6. Auclair E, Blondeel P, Del Vecchio DA. Composite breast augmentation: soft-tissue planning using implants and fat. *Plast Reconstr Surg*. 2013;132:558–568.
7. Tebbetts JB. Dual plane breast augmentation: optimizing implant-soft-tissue relationships in a wide range of breast types. *Plast Reconstr Surg*. 2001;107:1255–1272.
8. Hedén P, Bronz G, Elberg JJ, et al. Long-term safety and effectiveness of style 410 highly cohesive silicone breast implants. *Aesthetic Plast Surg*. 2009;33:430–436; discussion 437.
9. Maxwell GP, Gabriel A. Acellular dermal matrix for reoperative breast augmentation. *Plast Reconstr Surg*. 2014;134:932–938.
10. Auclair E, Anavekar N. Combined use of implant and fat grafting for breast augmentation. *Clin Plast Surg*. 2015;42:307–14, vii.
11. Moher D, Liberati A, Tetzlaff J, et al; PRISMA Group. Preferred reporting items for systematic reviews and meta-analyses: the PRISMA Statement. *Open Med*. 2009;3:e123–e130.
12. Bravo FG. Parasternal infiltration composite breast augmentation. *Plast Reconstr Surg*. 2015;135:1010–1018.
13. Kerfant N, Henry AS, Hu W, et al. Subfascial primary breast augmentation with fat grafting: a review of 156 cases. *Plast Reconstr Surg*. 2017;139:1080e–1085e.
14. Özalp B, Aydinol M. Breast augmentation combining fat injection and breast implants in patients with atrophied breasts. *Ann Plast Surg*. 2017;78:623–628.
15. Maione L, Caviggioli F, Vinci V, et al. Fat graft in composite breast augmentation with round implants: a new concept for breast reshaping. *Aesthetic Plast Surg*. 2018;42:1465–1471.
16. Sampaio Goes JC, Munhoz AM, Gemperli R. The subfascial approach to primary and secondary breast augmentation with autologous fat grafting and form-stable implants. *Clin Plast Surg*. 2015;42:551–564.
17. Auclair E. Benefit of complementary lipofilling in aesthetic breast augmentation with implant. *Ann Chir Plast Esthet*. 2009;54:491–495.
18. Góes JC, Landecker A. Optimizing outcomes in breast augmentation: seven years of experience with the subfascial plane. *Aesthetic Plast Surg*. 2003;27:178–184.
19. Graf RM, Bernardes A, Rippel R, et al. Subfascial breast implant: a new procedure. *Plast Reconstr Surg*. 2003;111:904–908.
20. McCarthy CM, Loyo-Berrios N, Qureshi AA, et al. Patient registry and outcomes for breast implants and anaplastic large cell lymphoma etiology and epidemiology (profile): initial report of findings, 2012–2018. *Plast Reconstr Surg*. 2019;143:65S–73S.
21. Coleman SR. Structural fat grafting. *Aesthet Surg J*. 1998;18:386–388.
22. Khater R, Atanassova P, Anastassov Y, et al. Clinical and experimental study of autologous fat grafting after processing by centrifugation and serum lavage. *Aesthetic Plast Surg*. 2009;33:37–43.
23. Rohrich RJ, Sorokin ES, Brown SA. In search of improved fat transfer viability: a quantitative analysis of the role of centrifugation and harvest site. *Plast Reconstr Surg*. 2004;113:391–395; discussion 396–397.
24. Li FC, Chen B, Cheng L. Breast augmentation with autologous fat injection: a report of 105 cases. *Ann Plast Surg*. 2014;73(suppl 1):S37–S42.
25. Rubin JP, Coon D, Zuley M, et al. Mammographic changes after fat transfer to the breast compared with changes after breast reduction: a blinded study. *Plast Reconstr Surg*. 2012;129:1029–1038.
26. Gutowski KA; ASPS Fat Graft Task Force. Current applications and safety of autologous fat grafts: a report of the ASPS fat graft task force. *Plast Reconstr Surg*. 2009;124:272–280.
27. Groen JW, Negenborn VL, Twisk JW, et al. Autologous fat grafting in cosmetic breast augmentation: a systematic review on radiological safety, complications, volume retention, and patient/surgeon satisfaction. *Aesthet Surg J*. 2016;36:993–1007.
28. Pusic AL, Reavey PL, Klassen AF, et al. Measuring patient outcomes in breast augmentation: introducing the BREAST-Q augmentation module. *Clin Plast Surg*. 2009;36:23–32, v.